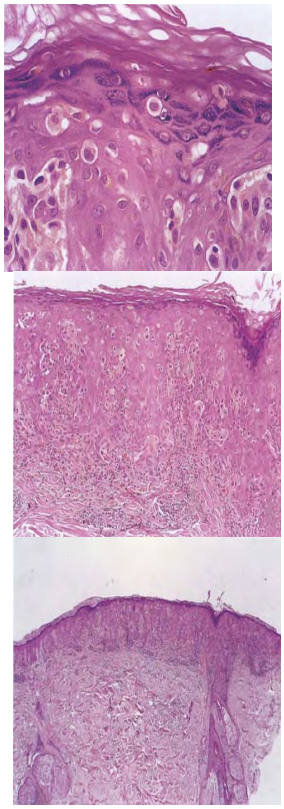

Superficial Spreading Melanoma

Superficial spreading melanoma, also referred to as pagetoid melanoma , is the most frequent form of m

Histopathology

. Architectural pattern features of importance in the diagnosis include the large di

Cytologically, the lesional cells are rather uniform and have abundant cytoplasm containing varying amo

When the lesion is *in situ,* the basement membrane is intact and there are no lesi

Histogenesis . On electron microscopic examination, melano-somes ar

more likely than other melanomas to be associated with BRAF or NRAS mutations . These evolving gen

Differential Diagnosis . A junctional nevus differs from *in situ* superficial spreading melan

When tumorigenic vertical growth phase is present, it does not differ appreciably from that in any other f

Among the nonmelanocytic neoplasms that must be differentiated from a *Paget's disease* of the *vulva* *superficial spreading melanoma* *microinvasive* *vulva* *Paget's disease*

antigen and keratin and are negative for HMB-45 and Melan-A. S100 reactivity, although unusual, may c

A final pitfall in evaluating nonmelanocytic mimics of intraepidermal melanoma involves the variable tend