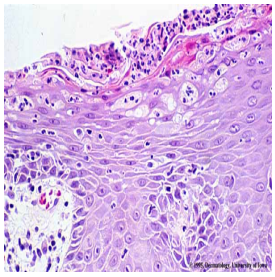

Psoriasis

Psoriasis may be divided into psoriasis vulgaris, generalized pustular psoriasis, and localized pustular ps

Psoriasis Vulgaris Clinical Features

Psoriasis vulgaris is a common chronic inflammatory skin disorder that affects approximately 1.5% to 2%

associated with acute group A ~-hemolytic streptococcal infections . Involvement of the nails is common

Psoriatic arthritis characteristically involves the terminal interphalangeal joints, but frequently the large jo

Generalized Pustular Psoriasis

Clinical Features

Generalized pustular psoriasis includes (a) acute generalized pustular psoriasis (von Zumbusch type an

This cutaneous eruption is characterized by the presence of variable numbers of sterile pustules appear

The four variants of generalized pustular psoriasis show considerable resemblance and overlapping in t

mainly in the mode of onset and the distribution of the lesions. Frequently, all four diseases show oral pu

Acute generalized pustular psoriasis *von Zumbusch* is generally diagnosed when the

Generalized pustular psoriasis of *pregnancy* is a rare pustular eruption *impetig*

In some instances of *subacute annular pustular psoriasis* *Herpes* or gyrate lesions show a clinical resemblanc

Very rarely, children develop generalized pustular psoriasis. The disease has a benign course with f

infantile and juvenile pustular psoriasis

Localized Pustular Psoriasis

Clinical Features

There are three types of localized pustular psoriasis: (a) "psoriasis with pustules" , in which only one or a

Acrodermatitis continua of *Hallopeau* is the term used when the pustu

Pustulosis palmaris et plantaris is a chronic, relapsing disorder occurring on the palms and soles, characterized by deep-seated pus

Psoriasis and Acquired Immunodeficiency Syndrome

Clinical Features

The association between psoriasis and human immunodeficiency virus (HIV) infection is common (109). Pa

Extensive erythroderma (psoriasis) is common (109). Sear

Psoriasis Vulgaris

Histopathology

The histologic picture of psoriasis vulgaris varies considerably with the stage of the lesion and usually is

The earliest pinhead-sized macules or smooth-surfaced papules show subtle histologic changes with a p

exocytosis of neutrophils, they may aggregate in the uppermost portion of the spinous layer to form sma

In the fully developed lesions of psoriasis, as best seen at the margin of enlarging plaques, the histologic

Of the listed features, only the spongiform pustules of Kogoj and Munro microabscesses are truly diagno

The rete ridges show considerable elongation and extend downward to a uniform level, resulting in regu

show thickening ("clubbing") in their lower portion. Not infrequently, adjacent rete ridges seem to coales

The suprapapillary epidermis appears relatively thin in comparison with the markedly elongated rete ridg

In some instances the cornified layer consists entirely of confluent parakeratosis forming a platelike scal

Munro microabscesses are located within the parakeratotic areas of the cornified layer . They consist of

The dermal papillae, in accordance with the elongation and basal thickening of the rete ridges, are elong

An entirely typical histologic picture as described earlier is not always found, even if the biopsy specimen

indicates a fluctuation in the activity of the psoriasis.

The bleeding points that may be produced by gentle scraping of the skin (Au spitz sign) correspond to th

Guttate or eruptive psoriasis shows the histologic features of an early or active lesion of psoriasis, where ther

The histologic picture of *erythrodermic psoriasis* in some instances shows enough of the characteristics o

Generalized Pustular Psoriasis

Histopathology

Whereas in ordinary psoriasis the spongiform pustule of Kogoj is a very small micropustule and is seen

In addition to the large spongiform pustules, the epidermal changes in generalized pustular psoriasis are

In the healing stage, the lesions of all types of generalized pustular psoriasis may present the same hist

Localized Pustular Psoriasis

Histopathology

In the variants of localized pustular psoriasis "psoriasis with pustules" and localized annular pustular ps

In localized acrodermatitis continua of Hallopeau, the nail bed is mainly affected, showing marked epithe

In pustulosis palmaris et plantaris there is a fully developed large intraepidermal unilocular pustule. It is c

the ustule, most commonly at the junction of the lateral walls and the overlying epidermis . These spong

Very early lesions may show spongiosis and exocytosis of lymphocytes in the lower epidermis overlying

Psoriasis and Acquired Immunodeficiency Syndrome

Histopathology

The histologic picture in most cases is similar to that of psoriasis. In others, the histologic sections may s

Pathogenesis* of *Psoriasis Vulgaris

Although the cause of psoriasis is unknown, there is increasing evidence of a complex interaction amon

Electron Microscopy

The earliest recognizable morphologic events in psoriasis have been investigated in lesions that cleared

Ultrastructural studies of the spongiform pustule of Kogoj, one of the most characteristic histologic struct

The ultrastructure of the capillary loops in the dermal papillae shows them to be different from normal ca

Epidermal Cell Cycle Kinetics

The rate of epidermal cell replication is markedly accelerated in active lesions of psoriasis, as shown by

Early calculations made it appear likely that in psoriatic lesions there was a great acceleration of the tran

Further investigations have found that (a) the generation time of epidermal cells is shorter, and (b) the epidermal turnover time is reduced from 311 to 36 hours, i

100% of the germinative cells of the epidermis enter the growth fraction instead of only 60% for normal s

The source of the cycling cells in the suprabasal layers of the epidermis is not well defined. They could b

Recent studies suggested that psoriatic epidermis shows aberrant expression of apoptosis-related mole

Keratinocyte Differentiation

Keratinocytes undergo the process of differentiation as they migrate upward through the epidermis from

Immunopathology

Immunologic factors playa very important role in the pathogenesis of psoriasis. Psoriasis is now regarde

CD4+ T cells produce a variety of cytokines, including interleukin-2 (IL-2), tumor necrosis factor-a (TN F

Keratinocytes stimulated by TNFa may produce IL-B, which is a potent T-lymphocyte and neutrophil che

yIFN is believed to play an important role in the initiation of psoriatic lesions as demonstrated by the indu

γIFN induces the expression of the ICAM-1 in keratinocytes and endothelial cells. This molecule mediate

not to be responsive to the growth inhibition effects of yIFN, leading to their hyperproliferative state in the

Increased expression of p53 and downregulation of Bcl-2, consistent with the dynamics of psoriasis, hav

Pathogenesis* of *Localized Pustular Psoriasis

A relationship of pustulosis palmaris et plantaris with psoriasis is not generally accepted, although two fa

Pathogenesis of Psoriasis and AIDS

There is evidence of the role of both CD8+ and CD4+ T lymphocytes and γIFN in the pathogenesis of ps

. Paradoxically, as T-helper cell counts decline, it appears that psoriatic lesions exacerbate until a prete

The immunodysregulation resulting from HIV infection may trigger psoriasis in those genetically predispo

Differential Diagnosis

Two histologic features are of diagnostic in the diagnosis of psoriasis vulgaris (a) macroscopically: (b) [illegible]

including Reiter's disease, *pustular dermatosis, bacterial impetigo, psoriasis, pustular eruptions,* particula

Because of the clinical and, particularly, the histologic resemblance of the tongue lesions in pustular pso