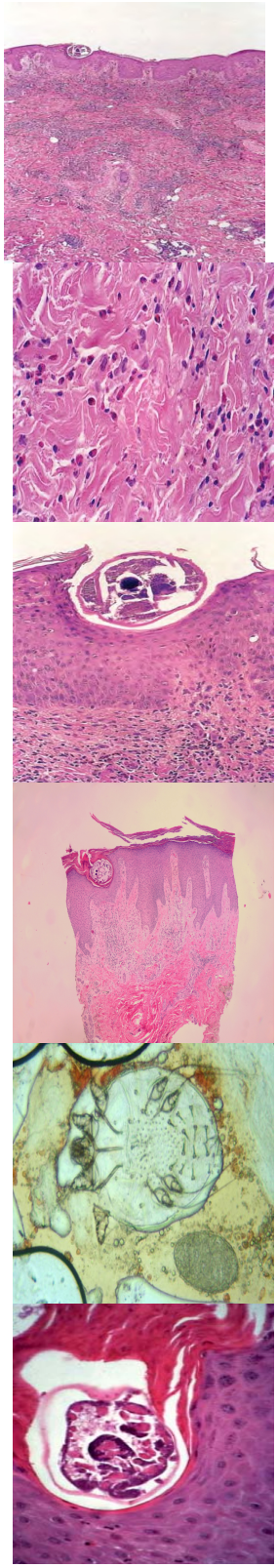

Scabies

Acarid mites produce several skin manifestations in humans, the most common, one represented by the

Sarcoptes scabiei *var. hominis*

Burrows are the pathognomonic lesions of scabies and are found mostly in the florid, papulovesicular typ

In some patients, itching nodules persist for several months after successful treatment, and therefore are

nodular scabies or persistent scabietic nodules. They are found most commonly on the scrotum and are

In a third, rare variant, the so-called Norwegian scabies or crusted scabies, innumerable mites are prese

Histopathology.

□ A definitive diagnosis of scabies can be made only by demonstration of the mite

Histologic examination of a specimen containing a burrow reveals that the burrow in almost its entire len

In the papulovesicular form of scabies, spongiosis is present in the stratum malpighii near the mite to su

In nodular or persistent nodular scabies, there is a dense, chronic inflammatory, often pseudolymphoma

In Norwegian scabies, the thickened horny layer is riddled with innumerable mites, so that nearly every s

Pathogenesis . Earlier scanning electron microscope studies revealed t