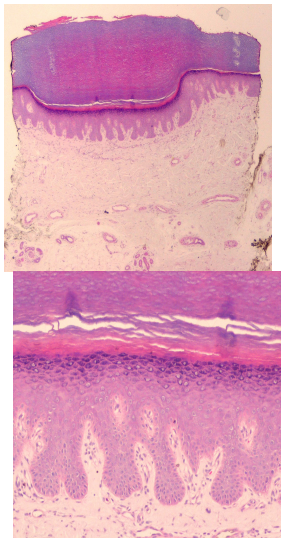

Keratosis Palmaris ET Plantaris

Three major autosomal dominant forms and two autosomal recessive forms of keratosis palmaris et plar

1. *Keratosis palmaris et plantaris* *Unna-*

- showing either diffuse or localized, occasionally linear hyperkeratosis of the palm

2. *Epidermolytic keratosis palmaris et plantaris* althoug

3 . Keratosis palmoplantaris {or punctata papulosa} has mu

The two recessively inherited forms include the following:

1. *Keratosis palmaris et plantaris* of *the Mel*

2. The *Papillon-Lefiwre syndrome* shows t

In addition, keratosis palmaris et plantaris occurs in three syndromes: {a} pachyonychia congenita, {b} h

16q22, 1-q22.3} (69).

Histopathology .

□ In keratosis palmaris et plantaris of the Unna-Thost type and the Meleda type, a

In epidermolytic keratosis palmaris et plantaris, the histologic picture is identical with that seen in epiderm

In keratosis palmoplantaris punctata, there is massive hyperkeratosis over a sharply limited area, with d