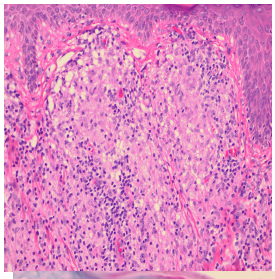
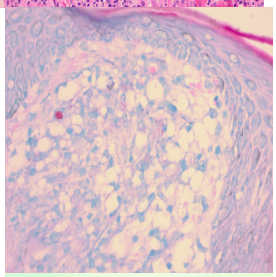
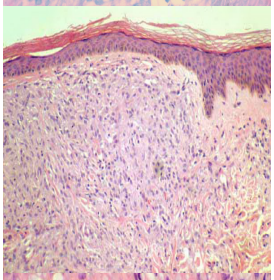
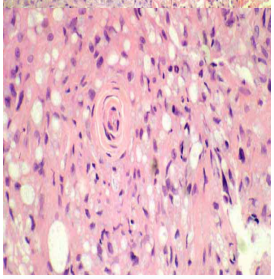
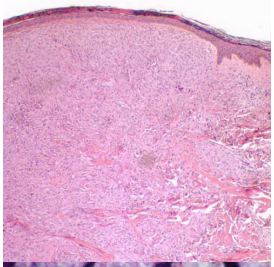
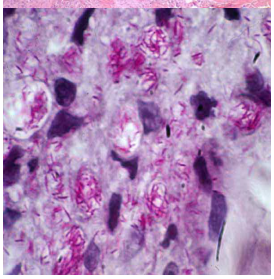

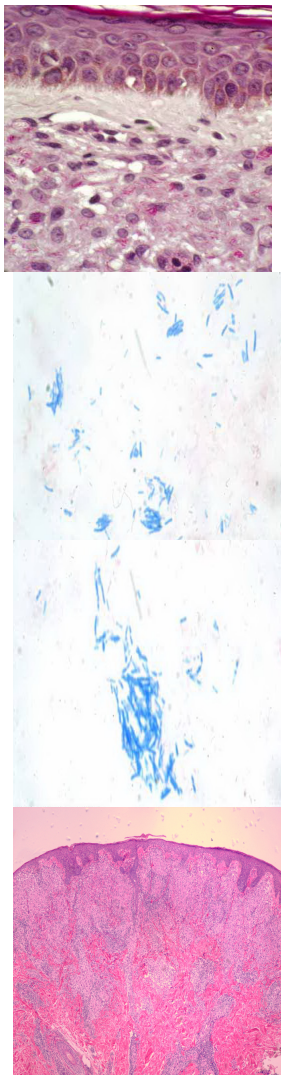

Leprosy

Leprosy is caused by M.*leprae* and predominantly affects the skin and peripheral nerve

Immunopathologic Spectrum of Leprosy

The sequence of disease *lepra*-pathogenesis is complex, very chronic, and depends on host-parasite interaction

TT and LL patients are stable, the former often self-healing and the latter remaining heavily infected unle

absence of treatment. The *M. leprae* spectrum (BB) is the most stable, with most patients de

It is likely that in endemic areas, a high proportion of people are infected by *M. leprae* but do not develop disease or have de

Staining of Mycobacterium leprae Bacilli

The classical method for demonstrating leprosy bacilli in lesions is a modified Ziehl-Neelsen stain, where

BI	=	0: no bacilli observed

- · BI = 1:
- · BI = 2:
- · BI = 3:
- · BI = 4:
- · BI = 5:
- · BI = 6:

Solid-staining bacilli indicate that the organisms are capable of multiplication. Fragmented (beaded) and

bacilli indicate that they *are dead*. Patients with no bacilli detectable in lesions *are* termed (this dis

Immunocytochemical methods for demonstrating mycobacterial antigens have a limited role. The most fr

Clinical Pathology **of** ***Leprosy***

For general discussions of clinical leprosy and leprosy pathology, the reader is referred to Job (147) and

Early, Indeterminate Leprosy

Many patients present with obvious or advanced skin and peripheral nerve lesions (the latter are primari

Histopathology .

There is mild lymphocytic and macrophage accumulation around neurovascular bundles, the

superficial and deep dermal vessels, sweat glands, and erector pili muscle; focal lymphocytic invasion in

A distinctive variant of lepromatous leprosy, the histoid type, first described in 196

Rarely, lepromatous leprosy can present as a single lesion rather than as multiple lesions (150).

Histopathology.

Lepromatous leprosy, in the usual macular or infiltrative form (Figs. 21-23). The exhibits an extensive cellular infiltration, an Wade-Fite staining

In time, and with anti my*cobac*terial chemotherapy, lepromatous leprosy, in contrast to the tuberculoid form, b

Histoid Leprosy

Histoid leprosy shows the highest loads of bacilli (frequently, the BI is 6), and the majority are solid stain

Histopathology .

□ The important difference between LL and BL leprosy histology is that in BL, the

□

Midborderline Leprosy

In midborderline (BB) leprosy, the skin lesions are irregularly dispersed and shaped erythematous plaqu

Histopathology. In BB leprosy, the macro phages are uniformly activated to epithelioid cells but a

Borderline Tuberculoid Leprosy

In borderline tuberculoid (BT) leprosy, the lesions are asymmetrical and may be scanty. They are dry, ha

Histopathology . Granulomas with peripheral lymphocytes follow the neu

and are not large in size. Granulomas along the superficial vascular plexus are frequent, but they do not

Tuberculoid Leprosy

The skin lesions of tuberculoid (TT) leprosy are scanty, dry, erythematous, hypopigmented papules or pl

Histopathology

. Primary TT leprosy has large epithelioid cells arranged in compact granulomas a

Peripheral Nerves

In all of these patterns of leprosy, the major peripheral nerves are often undergoing parallel pathologies.

Leprosy Reactions

Leprosy reactions are classified into two main types (1 and 2). A third reaction is specific to Lucio multiba

Type 1 Reactions

Because the immunopathogenic spectrum of leprosy is a continuum, patients may move along it in both

tuberoid

reversal reaction

Histopathology . The histopathology of type 1 reactions has still not been

there is edema within and about the granulomas and proliferation of fibrocytes in the dermis. In upgradin

□

□

type 2 Reaction: Erythema Nodosum Leprosum

Erythema nodosum leprosum (ENL) occurs most commonly in LL leprosy and less frequently in BL lepro

On the skin, tender, red plaques and nodules together with areas of erythema, and occasionally also pu

Histopathology. In ENL, the lesions are foci of acute inflammation superimposed on chronic mult

anti mycobacterial immunocytochemical stain (e.g., anti-BCG) will indicate abundant antigen. A necrotizi

Lucio Reaction

The Lucio reaction occurs exclusively in diffuse lepromatous leprosy, in which it is a fairly common comp

usually occurs in patients who have received either no treatment or inadequate treatment. In contrast to

Histopathology. In the Lucio reaction, vascular changes are critical . Endothelial proliferation lea

Electron Microscopy of Leprosy

Under electron microscopy, *M. leprae* can be seen to consist of an electron-dense cytoplasm l

Pathogenesis of Leprosy

With respect to immunological reactivity, patients with lepromatous leprosy show a defective cell-mediated

The specific inability of T lymphocytes obtained from patients with lepromatous leprosy to react against l

Analysis of T-cell subsets in lesions has shown that in tuberculoid leprosy, with its high degree of resista

In patients with either ENL or the Lucio reaction, deposits of IgG and the third component of complemen

The lepromin skin test, or *Mitsuda* test, consists of the intradermal injection of a preparation of *M. leprae* derived from armadillo infected tissue. A positive