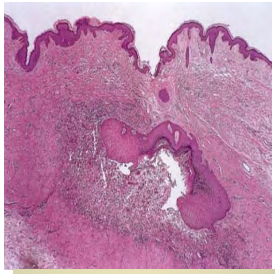

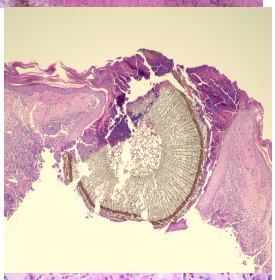

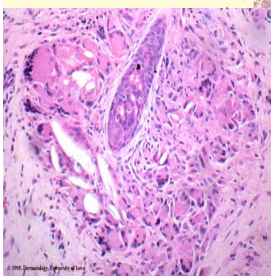

Foreign Body Reactions

Foreign substances, when injected or implanted accidentally into the skin, can produce a nonallergic for

□

□

Histopathology .

A *nonallergic* foreign-body reaction typically shows a granulomatous r

wood or other plant material , paraffin and other oily substances, silicone gel, talc, surgical glove starch p