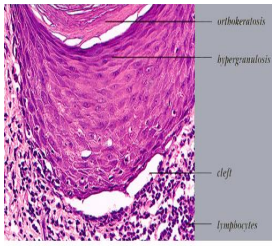

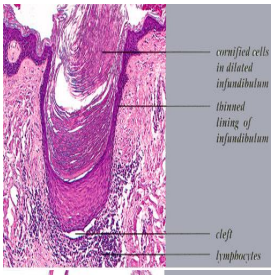

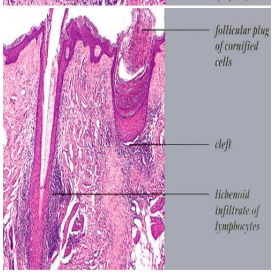

# **Alopecia of Lichen Planus =** المنبسط الحزاز بسبب الحاصة


orthokeratosis
hypergranulosis
cleft
lymphocytes


cornified cells in dilated infundibulum
thinned lining of infundibulum
cleft
lymphocytes


follicular plug of cornified cells
cleft
lichenoid infiltrate of lymphocytes

1 / 1