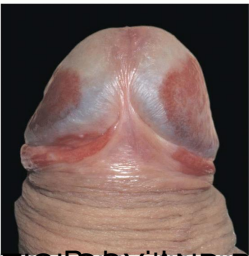
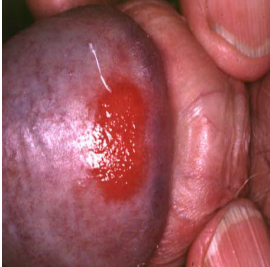







A most shiny, acrohemorrhagic, well-demarcated plaque on the glans penis in an older uncircumcised male is characteristic of Zoon's leukoplakia, also known as balanitis plasmacellularis. The condition is benign.



~~For a long time, the pathogenesis of this condition has been unclear. It is thought to be a form of leukoplakia, a precancerous condition. However, it is now generally accepted that it is a benign condition and does not lead to cancer. The condition is characterized by a well-demarcated, white, plaque-like lesion on the glans penis. It is most commonly seen in older, uncircumcised males. The condition is thought to be caused by a combination of factors, including chronic inflammation and changes in the local immune response. The condition is benign and does not require treatment, although it can be treated with topical steroids if it causes discomfort. The condition is named after the pathologist who first described it, Zoon.~~