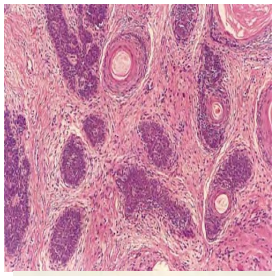

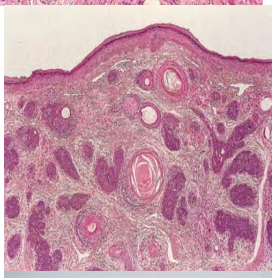

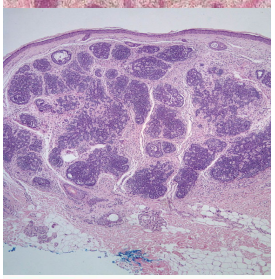

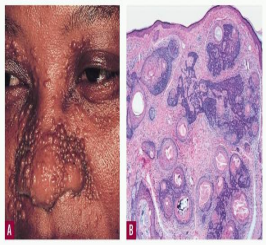
A
B

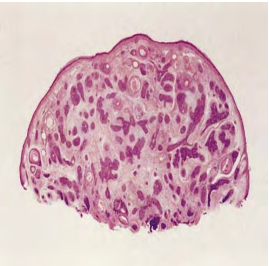

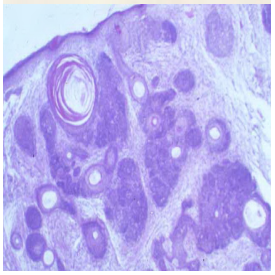

Trichoepithelioma

Trichoepithelioma occurs either in multiple lesions or as a solitary lesion. Trichoepithelioma is preferable to other designations, such as *trichoepithelioma adenoides cysticum*

Multiple trichoepithelioma 2 as are transmitted as an autosomal dominant trait (53). Located mainly in the fa and 8 mm in diameter are seen located mainly in the fa

Solitary trichoepithelioma occurs more commonly than multiple trichoepithelioma. It is not inherited and

Giant solitary trichoepithelioma, measuring several centimeters in diameter, is a distinct variant of trichoepithelioma

Histopathology .

□ As a rule, multiple trichoepitheliomas are superficial dermal lesions. They appea

. The fibroblasts encircle and are tightly associated with the basaloid islands, lacking the retraction artifa

Additional findings, observed in some but not all trichoepitheliomas, are the presence of a foreign-body g

Occasionally, some lesions in patients with multiple trichoepitheliomas show relatively little differentiation

carcinoma, which may also show horn cysts. Thus, on a histologic basis, it may be difficult definitively to

Solitary trichoepithelioma often has a high degree of differentiation toward hair structures. Solitary lesions

Additional Studies. It is assumed that the basophilic cells surrounding horn cysts are similar to hair

Histochemical staining with the Gomori stain for alkaline phosphatase has shown positive staining in ma

The putative gene for multiple familial trichoepithelioma has been localized to chromosome 9p21. Several

to function as an ubiquitin-specific protease, are present in some cases

The close relationship between trichoepithelioma and basal cell carcinoma has been explained on the

Differential Diagnosis . The difficulty of differentiating multiple trichoepithelioma

transmission. In addition, certain histologic features, as well as immunohistochemical stains, can assist i

The differentiation of multiple trichoepitheliomas from the nevoid basal cell carcinoma syndrome on histo