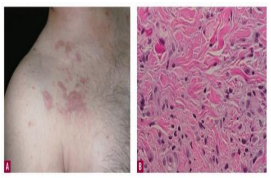

RHEUMATOID ARTHRITIS

Rheumatoid arthritis (RA) is a systemic inflammatory autoimmune disease that is characterized by a debilitating chronic, symmetric polyarthritis with significant extra-articular manifestations, which include rheumatoid nodules, pyoderma gangrenosum, granulomatous dermatitis, vasculitis, and internal organ involvement. The disease process is often progressive, resulting in limitation of joint function. Ultimately there may be a resultant decline in functional status, possibly leading to premature death. Permanent remission is unusual.

Epidemiology

Approximately 1 percent of the adult population in North America and Northern Europe are affected with RA, with great variation in prevalence in other parts of the world. Approximately 70 percent of patients follow a chronic disease course with exacerbations and remissions, 25 percent have intermittent disease with brief attacks of inflammation followed by remissions, and approximately 5 percent have an aggressive, malignant form with multiple extra-articular manifestations.[2] RA is more common in females than males, ratio from 2:1 to 3:1, and has a peak onset at 50 years of age.

Etiology and Pathogenesis

The exact etiology of RA remains unknown. The initial onset of joint symptoms is likely multifactorial. Genetics plays at least some role in the development, severity, and outcome of the disease in certain patients.[3] Furthermore, an association between extra-articular disease and HLA-DR1 and -DR4 genes has been noted in some populations.
[4]

Mechanical stress on joints may initiate an inflammatory response creating an imbalance between the rapid response to trauma and the need to protect

self from damage. Patients with seropositive RA (positive rheumatoid factor) have circulating and tissuebound immune complexes. B cells produce autoantibodies in some RA patients. After binding to antigen, these autoantibodies result in complement fixation and recruitment of polymorphonuclear leukocytes, which result in joint destruction. Possible antigens in RA include heat shock proteins, collagen, and cyclic citrullinated peptides.

RHEUMATOID ARTHRITIS AT A GLANCE

- ·
- ·
- ·
- ·
- ·
- ·

Patients with seronegative RA (negative rheumatoid factor) may not create autoantibodies, but other immune mechanisms are involved. This theory led to the recognition that T cells are important players in the etiology of this disease. In the SKG mouse model, autoreactive T cells are preferentially selected, leading to inflammatory arthritis similar to RA. T cells also activate other cells via cytokines, including osteoclasts, which play a major role in the bone resorption seen in RA. Effector cytokines of the T cell include interferon-γ, interleukin 1, interleukin 17, and tumor necrosis factor (TNF)-α, many of which have been, or are being, used as therapeutic targets to treat RA.

Lastly, joints have unique anatomic and physiologic qualities that render them targets for

immune and inflammatory assault. Cartilage is subject to repetitive mechanical stress, retains antigens and pro-inflammatory cytokines, and has a limited capacity for regeneration. Once proteolytic enzymes cause erosions, narrowing of the joint space, and mechanical instability, rheumatoid inflammation may become self-sustaining.

□ American College of Rheumatology Revised Criteria for the Classification of Rheumatoid Arthri

CRITERION

DEFINITION

Morning stiffness

Morning stiffness in and around the joints, lasting at least 1 h before maximal improvement.

Arthritis of three or more joint areas

At least three joint areas simultaneously afflicted with soft-tissue swelling or joint fluid observed by a phy

Arthritis of hand joints

At least one area swollen in a wrist, MCP, or PIP joint.

Symmetric arthritis

Simultaneous involvement of the same joint areas on both sides of the body (bilateral involvement of PIP

Rheumatoid nodules

Subcutaneous nodules over bony prominences or extensor surfaces or in juxta-articular regions (observe

Serum rheumatoid factor

Abnormal amount of serum rheumatoid factor by any method while the result has been positive in 5% of

Radiographic changes

Erosions or unequivocal bony decalcification localized in or most marked adjacent to the involved joints.

MCP, metacarpophalangeal; MTP, metatarsophalangeal; PIP, proximal interphalangeal.

From Arnett FC et al: The American Rheumatism Association 1987 revised criteria for the classification o *Arthritis Rheum* **31**:315, 1988.

Clinical Features

RA often begins with general constitutional symptoms such as fatigue, anorexia, vague musculoskeletal complaints, and generalized weakness. It may be weeks or months before the characteristic synovitis presents. It is in these early stages that definite diagnosis is most difficult, despite a thorough patient evaluation. However, early diagnosis and treatment are essential because most of joint damage is thought to occur early in the disease process. The American College of Rheumatology has guidelines for the diagnosis of RA (Table 161-1).[7] For a patient to be diagnosed with RA, four of the seven criteria must be present, and the first four criteria listed must be present for at least 6 weeks. Extra-articular manifestations may help to delineate the disease process early and may signify a more serious disease process requiring the initiation of aggressive therapy.

ARTICULAR MANIFESTATIONS

The articular manifestations of RA relate to an inflammatory synovitis that can affect the synovial lining of joints, tendons, and bursae. Synovial inflammation usually results in warmth but not erythema of the affected area. There is significant pain in association with stretching of the joint capsule. Hand and foot involvement forms the basis of the disease in most patients. Although the initial manifestations in the hand may be asymmetric, the clinical course subsequently takes on a symmetric and diffuse pattern. There is characteristic involvement of the proximal interphalangeal (PIP) and metacarpophalangeal joints with sparing of the distal interphalangeal (DIP) joints. The pattern of joint involvement is highly suggestive of the diagnosis.

Chronic inflammation may result in irreversible structural damage of the joint, including cartilage destruction and bony erosion. Late structural deformities may result from soft-tissue contractures or from bony ankylosis. Characteristic deformities include radial deviation of the

hand with ulnar deviation of the digits, the “swan neck” deformity from hyperextension of the PIP joint and compensatory flexion of the DIP joint, and the boutonnière deformity from flexion contracture of the PIP joint and extension of the DIP joint. Similar structural deformities can occur in the feet, and all can be debilitating. Involvement of the thoracic and lumbar spine in RA is exceptional. Although the shoulder joint is often affected, it is soft-tissue structures, which include the rotator

cuff tendons and muscles and the subacromial bursa, that are usually involved in the patient's symptomatology.

DERMATOLOGIC MANIFESTATIONS

Extra-articular manifestations occur in more aggressive or extensive forms of RA. The most common dermatologic finding in RA is the rheumatoid nodule. The classic rheumatoid nodule is a subcutaneous nodule that occurs in approximately one-fourth of patients with RA . More than 90 percent of patients with rheumatoid nodules have seropositive RA. The usual location is over pressure points such as the olecranon, the extensor surface of the forearms, and the Achilles tendon; but they have been described in almost every location, including viscera.[9] The main histologic findings are palisaded granulomas in the deep dermis or subcutaneous tissues with fibrinoid degeneration of collagen, a multitude of neutrophils, and neutrophilic dust, with surrounding fibrosis and proliferation of vessels. The main differential diagnoses histopathologically include subcutaneous granuloma annulare, necrobiosis lipoidica, foreign body or infectious granulomatous reaction, and epithelioid sarcoid.
[10]

Though rheumatoid nodules are benign, they can lead to complications, including ulceration, infection, joint effusion (rheumatoid chyliform bursitis), and fistulas (fistulous rheumatism). All conditions may lead to the need for surgical excision.[9]

Rheumatoid vasculitis has an estimated annual incidence of less than 1 percent, most often affects patients with seropositive disease, and is believed to affect 1 in 8 males with RA, versus

1 in 38 females.[11] Small- to medium-sized vessels are primarily affected, often with associated peripheral neuropathy (including motor), digital gangrene, nail fold infarcts, and palpable purpura (see Chap. 164). Some patients may have nail fold telangiectasias, with minute digital ulcerations or petechiae and digital pulp papules (Bywaters lesions) . These papules are a manifestation of mild vasculitis and typically occur without systemic signs of vasculitis. Histopathology of skin biopsy specimens usually shows leukocytoclastic vasculitis with neutrophilic infiltration of the vessel wall, fibrinoid necrosis, and hemorrhage without palisaded granulomatous reaction. [10] Cutaneous small vessel vasculitis mostly involves postcapillary venules and may affect arterioles and larger vessels of the viscera, heart, and central nervous system. The spectrum of clinical lesions reported in rheumatoid vasculitis is wide and varies with the size and location of the vessels involved and with the extent of the disease . Unfortunately, the presence of vasculitis, especially at the onset of the disease, portends a poor outcome. Patients with evidence of vasculitis affecting the skin should be started on aggressive therapy and followed closely for other organ involvement.

Rheumatoid vasculitis can present as lower-extremity ulcers; however, pyoderma gangrenosum should be suspected if deep liquefying ulcers with a characteristic purple, undermined border occur in patients with RA. The ulcers may occur at any site but are most common on the lower extremities and abdomen. Pyoderma gangrenosum occurs more frequently and more severely in females and may take years to heal. Leg ulcers may also appear in patients with Felty syndrome, a combination of chronic RA, hypersplenism, and leukopenia .

Rheumatoid neutrophilic dermatosis is a very rare cutaneous manifestation in patients with severe RA. First described by Ackerman in 1978, these lesions are

usually chronic, erythematous, and urticaria-like plaques and papules that are sharply marginated (Fig. 161-4A). Histopathologically, these lesions have a dense infiltrate of neutrophils without leukocytoclasia, in the setting of a mixed infiltrate and papillary edema . It may be difficult to differentiate rheumatoid neutrophilic dermatosis from acute febrile neutrophilic dermatosis (Sweet syndrome) .

Other vasculitis syndromes, such as erythema elevatum diutinum and livedo vasculitis (segmental hyalinizing vasculitis), have also been described in patients with RA. Skin manifestations such as palmar erythema, erythromelalgia, autoimmune bullous diseases such as epidermolysis bullosa acquisita , yellow nail syndrome , erythema multiforme , erythema nodosum , and urticaria also have been reported in patients with RA.

NON-DERMATOLOGIC EXTRA-ARTICULAR MANIFESTATIONS

In addition to systemic vasculitis, which can affect numerous organ systems, there are multiple non-dermatologic extra-articular manifestations of RA.

Laboratory Findings

There is no one specific histologic, radiographic, or laboratory test that conclusively permits the diagnosis of RA. Rheumatoid factor, an autoantibody that reacts with the Fc portion of immunoglobulin G (IgG), is found in sera of 85 percent of patients with RA. Rheumatoid factor should not be used as a definitive screening tool because it can be found in other disease processes (sarcoidosis, liver diseases, pulmonary fibrotic processes, and cryoglobulinemia). It is also found in approximately 5 percent of the unaffected population.[12] A false-positive rheumatoid factor can be caused by many factors, including chronic bacterial infections such as infective endocarditis, tuberculosis, and Lyme disease, as well as by viral diseases such as rubella and infectious mononucleosis.

□ Non-Dermatologic Extra-Articular Manifestations of Rheumatoid Arthritis

TYPE	**MANIFESTATIONS**
Ocular	

Keratoconjunctivitis sicca, scleritis, episcleritis, scleromalacia

Renal

Amyloidosis and vasculitis

Hematologic

Anemia, thrombocytosis, lymphadenopathy, Felty syndrome

Neurologic

Entrapment neuropathy, cervical myelopathy, mononeuritis multiplex (vasculitis), peripheral neuropathy

Lung

Pleural effusions, pulmonary fibrosis, bronchiolitis obliterans, rheumatoid nodules, vasculitis

Cardiac

Pericarditis, premature atherosclerosis, vasculitis, nodules, aortic root dilatation

Treatment

Because the exact cause of RA is unknown, treatment has been directed against various components of the inflammatory
process. No single therapy is the treatment of choice. In the past, most patients with early disease were started on nonsteroidal anti-inflammatory drugs until joint erosions were evident.

Box 161-1 Differential Diagnosis of Rheumatoid Nodules

Consider

- · Subcutaneous granuloma annulare
- · Foreign body granuloma
- · Infectious granuloma
- · Sarcoid granuloma
- · Myxoid cyst
- · Traumatic epidermal cyst
- · Xanthoma

Rule Out

- · Epithelioid sarcoma
- · Fibromatous nodules in Lyme borreliosis

These medications are useful to alleviate symptoms. They do not alter disease progression.

Furthermore, new understanding of disease mechanism and the chronic disabling nature of RA has resulted in a shift to earlier use of disease-modifying anti-rheumatic drugs (DMARDs). New guidelines released by the American College of Rheumatology in 2002 advocate this switch. DMARDs decrease inflammation (confirmed by a reduction in acute phase reactants), reduce or prevent joint damage, and modify the disease process. The use of DMARDs is now recommended early in the disease course, when joint damage has already occurred or is imminent. Multiple medications fall into this category . They may be used alone or in combination, but their use may be limited by loss of efficacy or systemic toxicity. Medications are often used in combination, but the decision about which drug to use is often individualized and determined by the clinical severity and loss of function and resultant disability, along with concerns about the safety profile of each given patient.

Disease-Modifying Anti-Rheumatic Drugs

- Methotrexate
- Hydroxychloroquine
- Gold salts
- Sulfasalazine
- Azathioprine
- Cyclosporine
- Cyclophosphamide
- Leflunomide
- D-Penicillamine

Systemic glucocorticoids are potent anti-inflammatory agents but have a serious side-effect profile when used in large doses over long periods of time. They are not a good option alone for RA, but are sometimes used in a low dose with other DMARDs. Methotrexate has been used as a very effective DMARD for many years.

The newest additions to the anti-rheumatic armamentarium are the biologic response modifiers, which act to inhibit the pro-inflammatory cytokines that play a role in RA. The best known commercially available members of this category are the anti-TNF-α agents. TNF-α is a pro-inflammatory agent released by macrophages and T cells contributing to synovitis and joint destruction.

There are three anti-TNF-α drugs currently approved by the U.S. Food and Drug Administration for the treatment of RA: etanercept, infliximab, and adalimumab. Etanercept is a recombinant human TNF dimeric receptor fusion protein consisting of the ligandbinding portion of the human 75-kd TNF receptor linked to the Fc portion of human IgG1. This treatment is given as a subcutaneous injection twice per week. Infliximab is a chimeric (mouse/human) IgG1 monoclonal antibody to TNF-α. It is given intravenously every 6 to 8 weeks. Last, adalimumab, the newest of these agents, is a human IgG1 monoclonal antibody that binds membrane bound and soluble TNF-α.[15] Etanercept, infliximab, and adalimumab render TNF-α biologically inactive, thereby significantly decreasing the synovitis and retarding the progression of joint destruction.

There are a number of limitations to the use of biologic response modifiers. They are expensive, ranging between 18,000 to 30,000 dollars per year, and both etanercept and adalimumab require the patient to self-administer injections. Not all patients are willing to do this. Infliximab, on the other hand, is an infusion, which inherently requires that the patient have more time from work/home and lends itself to the possibility of infusion reactions. In addition, there needs to be an infusion center nearby where the patient can receive therapy. Most patients receiving TNF-α blocking agents have failed therapy with one or a combination of the previously mentioned DMARDs. Inhibiting the normal host immune response has led to concern about re-activation of tuberculosis, increased susceptibility to other infections, and predisposition to the development of malignancy. The true risk of malignancy is difficult to establish because patients with RA are thought to have a higher incidence of lymphoid malignancy than the normal population and some have shown that the incidence of lymphomas may in fact be increased in patients taking anti-TNF-α drugs.[17] As with all medications, knowing your patient's medical history is the key to proper use of these medications. They should not be used in patients with concurrent serious infection or in those predisposed to serious infections (patients with poorly controlled diabetes). Extreme caution and consultation with the hematologist-oncologist should be used before prescribing these medications to patients with a recent history of malignancy.

In conclusion, the dermatologist and rheumatologist must function as a cohesive team in the treatment of patients with cutaneous manifestations of RA, which often present during phases of intense disease activity. Patients need their underlying rheumatic disease to be treated aggressively, but proven treatments for these associated dermatologic processes, such as pyoderma gangrenosum, cryoglobulins, vasculitis, and others, should not be forgotten. These

specific treatment regimens are beyond the scope of this chapter.

.