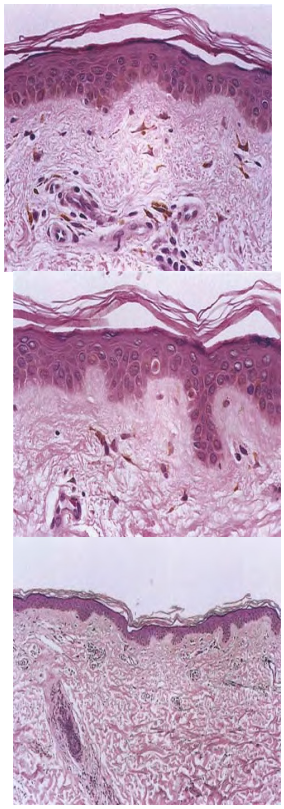

Post inflammatory hyperpigmentation = فرط التصبغ التالي للالتهاب

POST

INFLAMMATORY

1 / 2

Post inflammatory hyperpigmentation = فرط التصبغ التالي للالتهاب

HYPERPIGMENTATION

Post-inflammatory hyperpigmentation (PIH) is a common condition caused by numerous preceding cutaneous insults such as drug and phototoxic reactions , infections (see elsewhere), physical injury or trauma, allergic reactions, and inflammatory diseases. Clinically, PIH consists of a macular hyperpigmentation at the site of inflammation It is far more common and persistent in darker skin types and can be characterized by epidermal as well as dermal melanotic hypermelanosis. A Wood's lamp examination can determine depth of the hyperpigmentation . Histologic features include pigment incontinence with accumulation of melanophages and increased melanin in dermal or epidermal layers

2 / 2