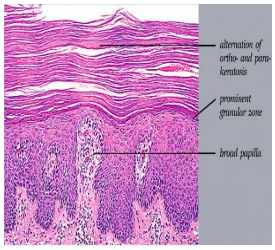

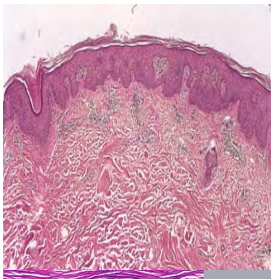

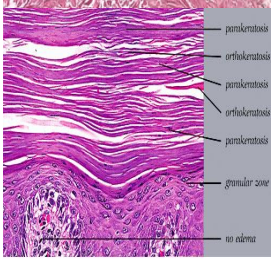

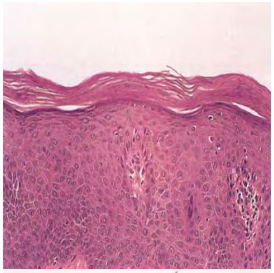

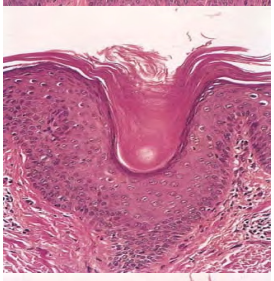

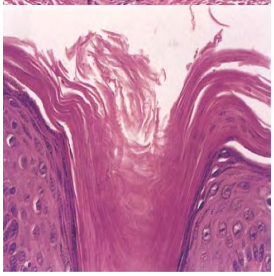

Pityriasis rubra pilaris= الجرابية الحمرا ء النخالية

alternation of ortho- and para-keratosis
prominent granular zone
broad papilla

parakeratosis
orthokeratosis
parakeratosis
orthokeratosis
parakeratosis
granular zone
no edema

1 / 2

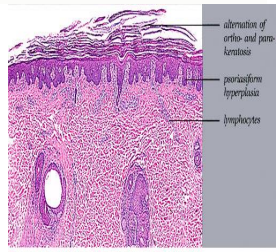

[redacted]

Consider
Always Rule
Systemic