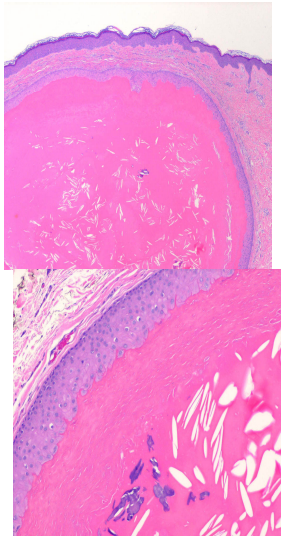

Pilar Cyst

Pilar or trichilemmal cysts are clinically indistinguishable from epidermal cysts but differ from them in fre

Histopathology.

The epithelial cells close to the cystic cavity appear swollen and are filled with pale cytoplasm . These sw

Whereas focal calcification of the cyst content does not occur in epidermal cysts, foci of calcification are

Trichilemmal cysts frequently disclose small, acanthotic foci in their walls that are indistinguishable from

Pathogenesis .

□ Pilar cysts were originally called sebaceous cysts. The name was changed whe

Electron microscopic examination of the epithelial lining of trichilemmal cysts shows that, on their way fr

Differential Diagnosis . Even though both the pilar cyst and the proliferating tric