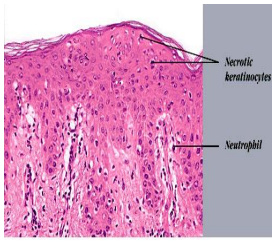

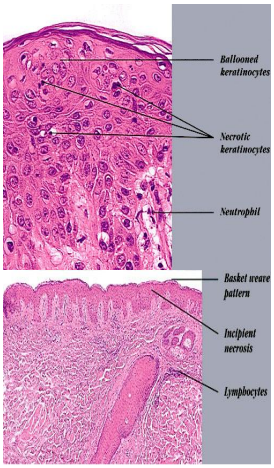

Phototoxic Dermatitis = الضيائي الانسمامي الجلد التهاب

Necrotic keratinocytes
Neutrophil

Ballooned keratinocytes
Necrotic keratinocytes
Neutrophil

Basket weave pattern
Incipient necrosis
Lymphocytes

1 / 1