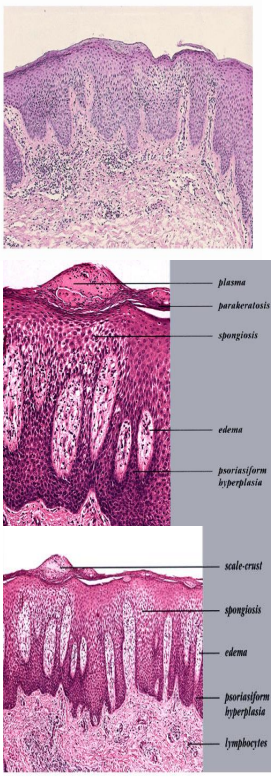

Nummular Dermatitis = **=** المدنر الجلد التهاب المدنرة الاكزيمة

plasma
parakeratosis
spongiosis
edema
psoriasiform hyperplasia

scale-crust
spongiosis
edema
psoriasiform hyperplasia
lymphocytes

Nummular Dermatitis

In nummular dermatitis, the eruption is characterized by pruritic, coin-shaped (nummular), erythematous

1 / 2

Nummular Dermatitis = = المدنر الجلد التهاب المدنرة الاكزيمة

Histopathology . Nummular dermatitis is the prototype of subacute spong

There is superficial perivascular infiltrate of lymphocytes, some eosinophils, occasional neutrophils, and

Pathogenesis. The etiology of this entity is unknown. The routine and ultrastructural changes ir

2 / 2