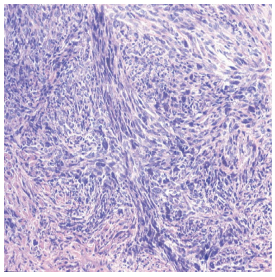

Malignant Blue Nevus

There exist potentially malignant melanocytic neoplasms that are unusual and do not necessarily qualify

Histopathology .

Recognition of the lesion as a malignant blue nevus rather than a common melanoma is based on the al

In addition to showing the standard features of malignancy, such as invasiveness of the tumor, atypia wi

Histogenesis . Although some authors have regarded the tumor cells a

Differential Diagnosis . Malignant blue nevus differs from conventional primary