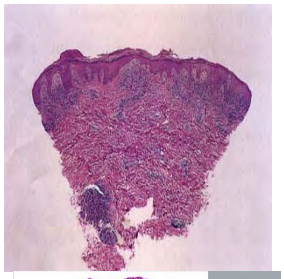

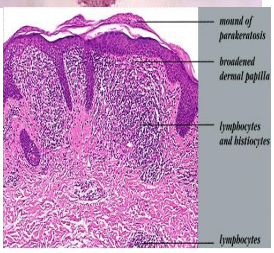
mound of parakeratosis
broadened dermal papilla
lymphocytes and histiocytes
lymphocytes

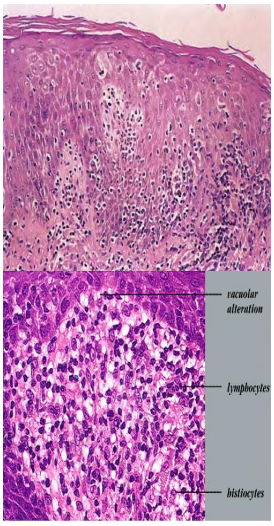
vacuolar alteration
lymphocytes
histiocytes

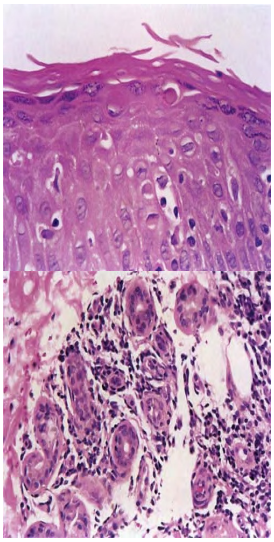

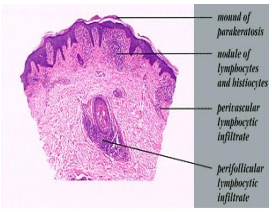

Lichen striatus = الحزاز الخطي

mound of parakeratosis
nodule of lymphocytes and histiocytes
perivascular lymphocytic infiltrate
perifollicular lymphocytic infiltrate

2 / 2