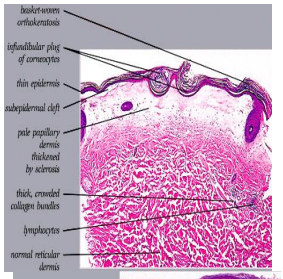
basket-woven orthokeratosis
infundibular plug of cornuocytes
thin epidermis
subepidermal cleft
pale papillary dermis thickened by sclerosis
thick, crowded collagen bundles
lymphocytes
normal reticular dermis

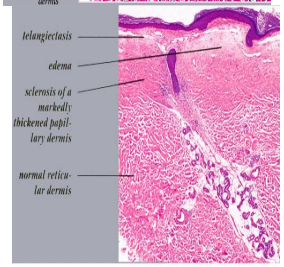
telangiectasis
edema
sclerosis of a markedly thickened papillary dermis
normal reticular dermis

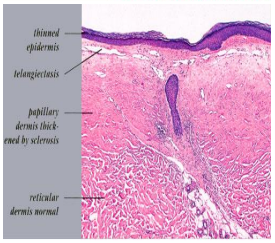
thinned epidermis
telangiectasis
papillary dermis thickened by sclerosis
reticular dermis normal

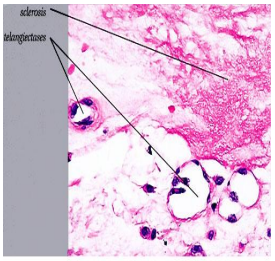
sclerosis
telangiectases

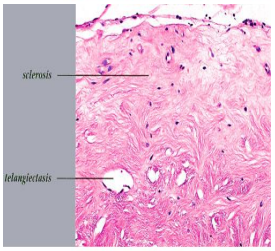
sclerosis
telangiectasis

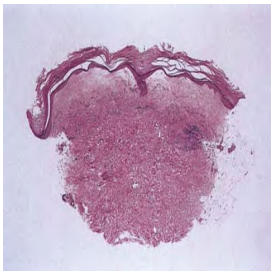

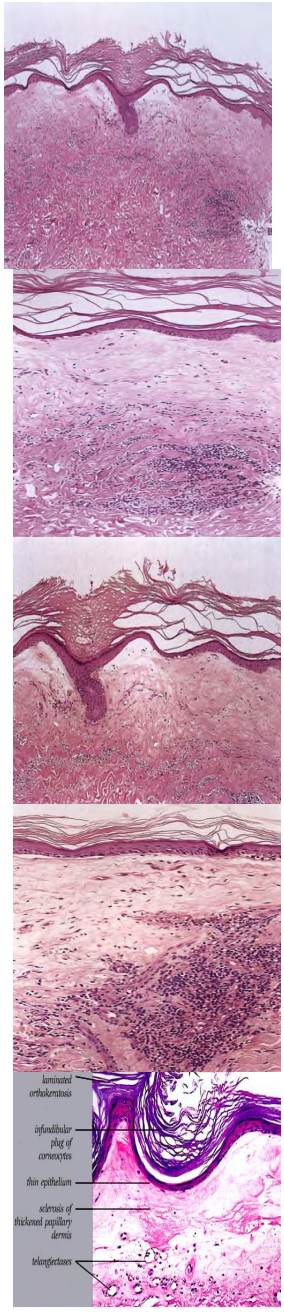

Lichen Sclerosus ET Atrophicus

Lichen sclerosus (LS) encompasses the disorders formerly known as lichen sclerosus et atrophicus (LSA), balanitis xerotica obliterans (BXO), and (LS of t

Lesions of LS are characterized by white polygonal papules that coalesce to form plaques. Comedo-like

In male patients, involvement of the glans and prepuce often results in phimosis. Although the literature

In female patients, contiguous involvement of the labial, perineal, and anal areas has been described cli

or "keyhole" lesions (165). Many cases of childhood LS in girls resolve by menarche (166). If lesions per

The premalignant potential in LS has been debated extensively and remains ill defined. The most recent

Of interest, lesions of LS may koebnerize (be provoked by trauma) as well as coexist with morphea (167

recognized by finding pale superficial dermal collagen, as compared with hypocellular compacted deep c

Histopathology.

□ The salient histologic findings in cutaneous lesions of lichen sclerosus et atrophi

The hyperkeratosis is so marked that the horny layer is often thicker than the atrophic stratum malpighii,

Keratotic plugging of appendageal ostia is often associated with atrophy and disappearance of appenda

Beneath the epidermis is a broad zone of pronounced lymphedema . Within this zone, the collagenous f

Except in lesions of long *sclerosus*, an inflammatory infiltrate is present in the dermis. This may be seen in les

Pathogenesis . Changes in the dermal matrix have been detected in LS

lack cross-striation, and in cross sections they sometimes have the appearance of empty tubes, suggest

The frequent finding of human papillomavirus alterations in lesions of LS have lead some to consider LS

changes in cases of other

chronic vulvar dermatitides. It has been hypothesized that persistent antigen may lead to the presence o

In the epidermis, intercellular edema separates epidermal cells that show degenerative changes. There

Differential Diagnosis .

□ Very early lesions may resemble lichen planus because of the apposition of the

Old lesions of lichen sclerosus et atrophicus with thickening and eosinophilia of the collagen bundles in t