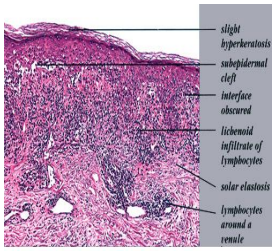
slight hyperkeratosis
subepidermal cleft
interface obscured
lichenoid infiltrate of lymphocytes
solar elastosis
lymphocytes around a venule

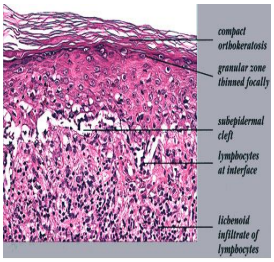
compact orthokeratosis
granular zone thinned focally
subepidermal cleft
lymphocytes at interface
lichenoid infiltrate of lymphocytes

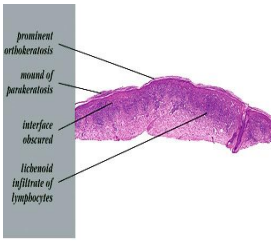
prominent orthokeratosis
mound of parakeratosis
interface obscured
lichenoid infiltrate of lymphocytes

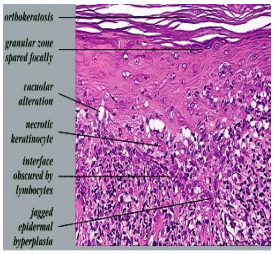
orthokeratosis
granular zone spared focally
vacuolar alteration
necrotic keratinocyte
interface obscured by lymhocytes
jagged epidermal hyperplasia

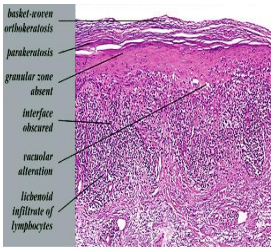
basket-woven orthokeratosis
parakeratosis
granular zone absent
interface obscured
vacuolar alteration
lichenoid infiltrate of lymphocytes

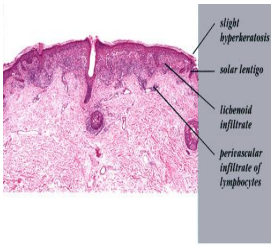
slight hyperkeratosis
solar lentigo
lichenoid infiltrate
perivascular infiltrate of lymphocytes