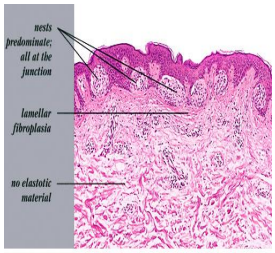
nests predominate; all at the junction
lamellar fibroplasia
no elastotic material

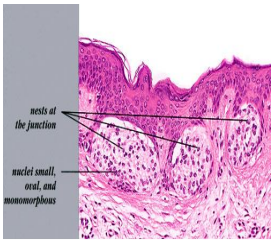
nests at the junction
nuclei small, oval, and monomorphous

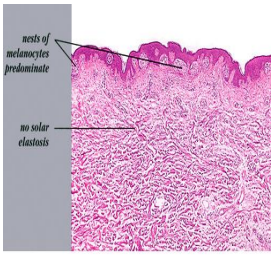
nests of melanocytes predominate
no solar elastosis