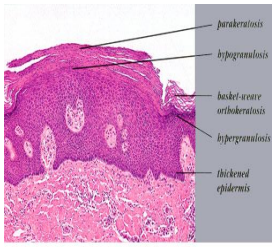

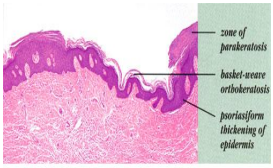

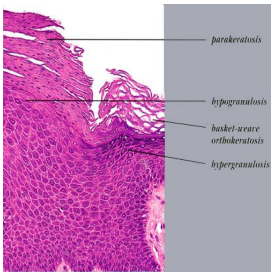

Linear Epidermal Nevus

Linear epidermal nevi, or verrucous nevi, may be either localized or systematized.

In the *localized type,* which is present usually but not invariably at birth, in its c

In the *systematized type,* papillomatous hyperkeratotic papules in a linear configu

Localized and, more commonly, systematized linear epidermal nevi may be associated with skeletal defo

The presence of a basal cell epithelioma within a linear epidermal nevus has been observed occasionall

Histopathology .

- Nearly all cases of the localized type of linear epidermal nevus and some cases

keratosis .

Occasionally in cases of *the localized type, keratosis* frequently in cases *of the systematized type,* partic

found to occur in several other conditions as well (see Isolated and Disseminated Epidermolytic Acantho

In some instances, histologic examination of unilateral linear lesions reveals features of acantholytic dys

Differential Diagnosis .

□ The histologic picture of a benign papilloma, as found in most cases of linear ep