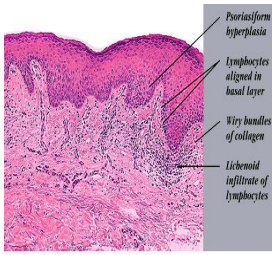

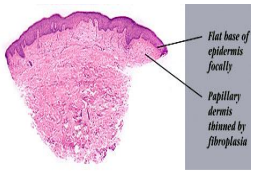

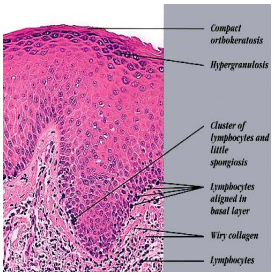

Erythroderma of mycosis fungoides = الكمئي التفطر في الجلد احمرية

Psoriasiform hyperplasia
Lymphocytes aligned in basal layer
Wiry bundles of collagen
Lichenoid infiltrate of lymphocytes

Flat base of epidermis focally
Papillary dermis thinned by fibroplasia

Compact orthokeratosis
Hypergranulosis
Cluster of lymphocytes and little spongiosis
Lymphocytes aligned in basal layer
Wiry collagen
Lymphocytes

1 / 1