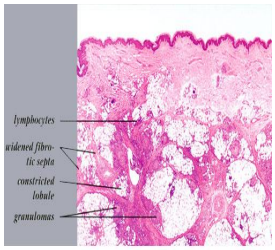

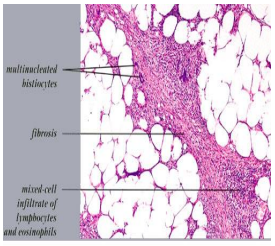

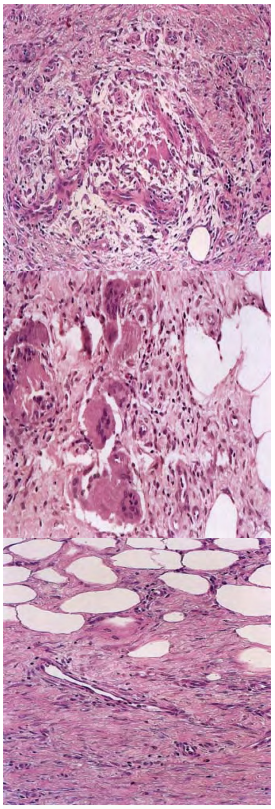

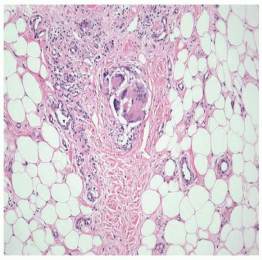

Erythema Nodosum = العقدة الحمامى

lymphocytes
widened fibrotic septa
constricted lobule
granulomas

multinucleated histiocytes
fibrosis
mixed-cell infiltrate of lymphocytes and eosinophils

1 / 20

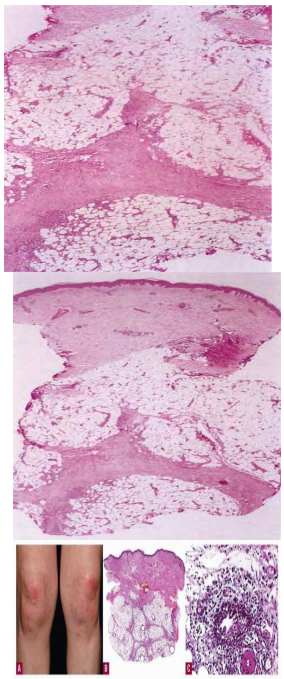

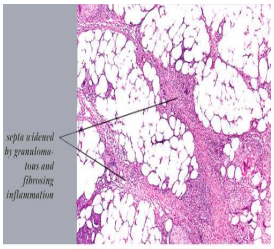

Erythema Nodosum = العقدة الحمامى

A
B
C

septa widened by granulomatous and fibrosing inflammation

Erythema Nodosum

2 / 20

Erythema Nodosum = العقدة الحمامى

Clinical Presentation. An acute form and a chronic form of erythema nodosum exist, which differ in th

In the *acute form* of erythema nodosum, there is a sudden appearance of

3 / 20

Erythema Nodosum = العقدة الحمامى

4 / 20

Erythema Nodosum = العقدة الحمامى

The *chronic form* of erythema nodosum is also known as *erythema nodosum migrans*

Histopathology. The histologic changes are present mainly in and near the septa of the subcutan

. The overlying dermis often has only a minimal to moderate, superficial and deep perivascular lymphoc

5 / 20

Erythema Nodosum = العقدة الحمامى

In the *early lesions* of *acute erythema nodosum,* there is

into the periphery of the [illegible]

6 / 20

Erythema Nodosum = العقدة الحمامى

7 / 20

Erythema Nodosum = العقدة الحمامى

8 / 20

Erythema Nodosum = العقدة الحمامى

erythema nodosum that is secondary to medications or estrogenic oral contraceptives.

Later lesions of acute erythema nodosum show widening of the septa, often with fibrosis and

9 / 20

Erythema Nodosum = العقدة الحمامى

when late lesions are compared with early ones . The granulomas often are loosely formed with macrop

10 / 20

Erythema Nodosum = العقدة الحمامى

In *chronic erythema nodosum,* the histologic findings are generally similar to those of th *erythema nodosum in* cases

11 / 20

Erythema Nodosum = العقدة الحمامى

Pathogenesis .

12 / 20

Erythema Nodosum = العقدة الحمامى

- Although the cause of erythema nodosum cannot always be determined [illegible]

13 / 20

Erythema Nodosum = العقدة الحمامى

14 / 20

Erythema Nodosum = العقدة الحمامى

15 / 20

Erythema Nodosum = العقدة الحمامى

lymphocytic vasculitis, which is predominantly lobular in distribution *(35).* Erythema nodosum and Sweet's syndrome have been r

Direct immunofluorescence studies have shown deposits of immunoglobulins only very rarely in the blo

16 / 20

Erythema Nodosum = العقدة الحمامى

The occurrence of erythema nodosum as a response to medications and to tuberculin skin testing in pat

nodosum . In approximately 50% of cases, there is no cause identified . The predilection for the anterior

17 / 20

Erythema Nodosum = العقدة الحمامى

Differential Diagnosis .

18 / 20

Erythema Nodosum = العقدة الحمامى

- Erythema nodosum needs to be distinguished from *erythema induratum* and *nodular*

19 / 20

Erythema Nodosum = العقدة الحمامى

20 / 20