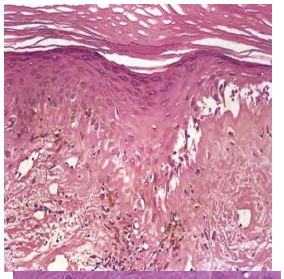

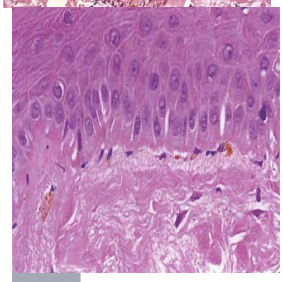

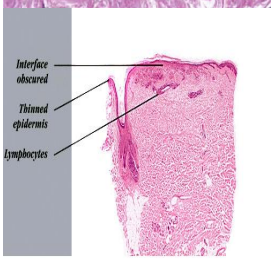

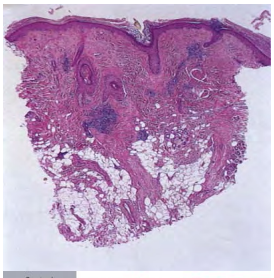

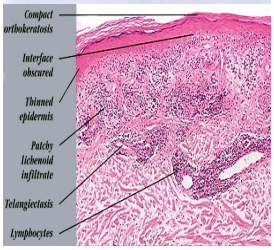

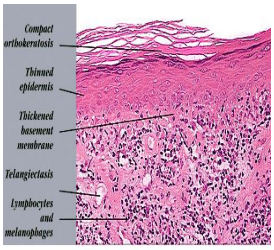

Discoid LE= القرصية الحمامية الذئبة

Interface obscured
Thinned epidermis
Lymphocytes

Compact orthokeratosis
Interface obscured
Thinned epidermis
Patchy lichenoid infiltrate
Telangiectasis
Lymphocytes

Compact orthokeratosis
Thinned epidermis
Thickened basement membrane
Telangiectasis
Lymphocytes and melanophages

1 / 3

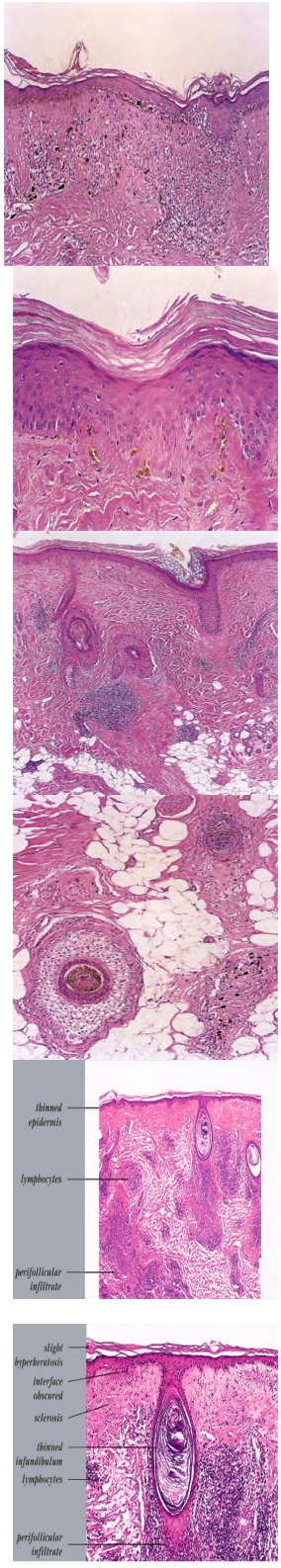

Discoid LE= القرصية الحمامية الذئبة

thinned epidermis
lymphocytes
perifollicular infiltrate

slight hyperkeratosis
interface obscured
sclerosis
thinned infundibulum
lymphocytes
perifollicular infiltrate

2 / 3

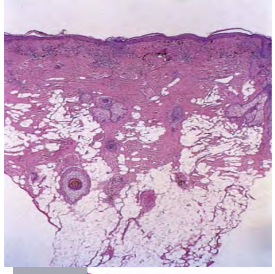

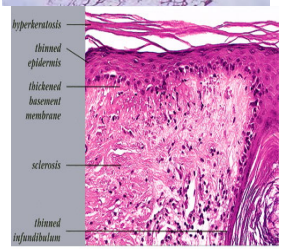

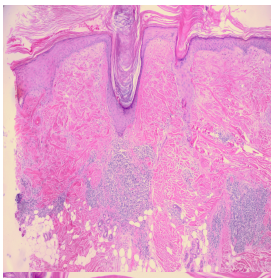

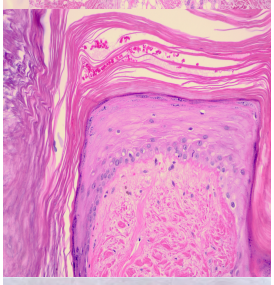

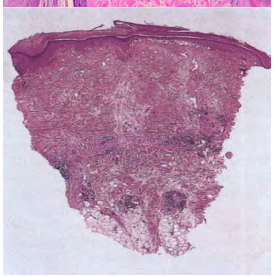

Discoid LE= القرصية الحمامية الذئبة

hyperkeratosis
thinned epidermis
thickened basement membrane
sclerosis
thinned infundibulum

3 / 3