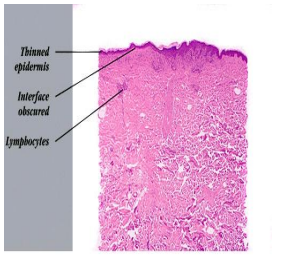

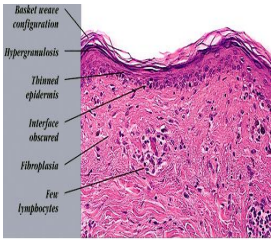

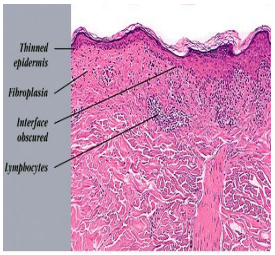

Atrophic lichen planus = الضموري المنبسط الحزاز

Thinned epidermis
Interface obscured
Lymphocytes

Basket weave configuration
Hypergranulosis
Thinned epidermis
Interface obscured
Fibroplasia
Few lymphocytes

Thinned epidermis
Fibroplasia
Interface obscured
Lymphocytes

1 / 1