Dermographic urticaria= القرطاسي الجلد = الجلدية الكتوبية

HIVE

1 / 8

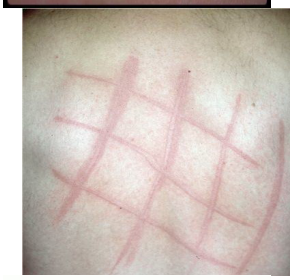

Dermographic urticaria= الجلدية الكتوبية = القرطاسي الجلد

2 / 8

Dermographic urticaria= الجلدية الكتوبية = القرطاسي الجلد

3 / 8

Dermographic urticaria= الجلدية الكتوبية = القرطاسي الجلد

4 / 8



Dermographic urticaria= الجلدية الكتوبية = القرطاسي الجلد

[illegible]

History

Whealing usually develops within 5-10 minutes of stroking the skin and persists for 15-30 minutes. A short refractory period after clearance of the wheal has been reported. Giant wheals can develop if deep extension of the swelling occurs.

- Intermediate and delayed forms of dermographism are also described. These develop more slowly and can last several hours to days.

5 / 8

- In patients with symptomatic dermographism, the skin eruption is associated with itching, which is often most severe at night.
- Symptoms can be aggravated by heat (hot bath), minor pressure (scratching, friction from clothes or from rubbing with towels), exercise, stress, and emotion.

Physical

Itching and whealing can affect all body surfaces, but the scalp and genitalia are less frequently involved. However, dyspareunia and vulvodynia have been reported in patients with symptomatic dermographism. [3] Rarer forms of dermographism include the following:

- Red dermographism: Repeated rubbing induces small, punctate wheals that are more prominent on the trunk than on the limbs. This form is possibly associated with seborrheic dermatitis.
- Follicular dermographism: Transitory, discrete, follicular, urticarial papules occur on a bright erythematous background.
- Cholinergic dermographism: A large erythematous line studded with punctate wheals similar to cholinergic urticaria (wheals smaller than classic urticaria and surrounded by large areas of macular erythema). Purpura has been noted in severe cases. It can be associated with cholinergic urticaria.
- Delayed dermographism: Approximately 3-8 hours after the immediate dermographic response, a deep, tender, burning wheal returns to the same site and persists for up to 48 hours. This form is recalcitrant to conventional therapy and is closely related to pressure urticaria.
- Cold precipitated dermographism: One case report has been published. [4]
- Exercise-induced dermographism
- Familial dermographism: One case report has been published. It is probably inherited as an autosomal dominant trait. [5]

Causes

Symptomatic dermographism is usually idiopathic. It may have an immunologic basis in some patients. Passive transfer of the dermographic response with immunoglobulin E– or immunoglobulin M–containing serum has been reported but no allergen has been identified.

- Symptomatic dermographism may be triggered by drugs (eg, penicillin), an insect bite, *Helicobacter pylori* infection, or an infestation (eg, scabies, *Fasciola hepatica*).

- Congenital symptomatic dermographism has been described as the first sign of systemic mastocytosis. [6]
- Approximately 75% of patients with hypereosinophilic syndrome, which has multisystem involvement and high mortality, have dermographism.
- Psychologic factors and a history of stressful life events have been implicated as triggering factors in 30% of patients. [7] However, a small prospective study showed no alteration in dermographic reaction following social stress provocation tests. [8]

- One case report describes symptomatic dermographism secondary to trauma from a coral reef.

Other Problems to Be Considered

Systemic mastocytosis and urticaria pigmentosa are associated with a positive Darier sign.

Forms of false dermographism (misnomers, not associated with urticaria) include (1) white dermographism, which is a blanching response resulting from capillary vasoconstriction following skin stroking and is more pronounced in persons with atopy; (2) black dermographism, which is black or greenish discoloration of the skin after contact with certain metallic objects; and (3) yellow dermographism, which probably results from bile pigment deposits in the skin.

Workup

Laboratory Studies

- The results from hematological and biochemical screening tests are normal. In some patients, an increase in blood histamine levels is seen after experimental scratching.

Procedures

- The diagnosis is usually made by observing the clinical response after using moderate pressure to stroke or gently scratch the skin. The site is important because areas protected from regular pressure and environmental influences, such as the back, are more reactive than more exposed areas, such as the buttocks and limbs.

Dermographic urticaria= الجلدية الكتوبية = القرطاسي الجلد

- A dermographometer (spring-loaded stylus) can be used to apply graded, reproducible pressure (eg, 3600 g/cm^2) and record skin responses. It is mostly limited to research settings.

Histologic Findings

- Biopsy specimens show dermal edema with a few perivascular mononuclear cells.

8 / 8