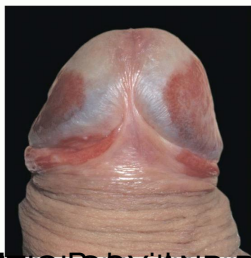
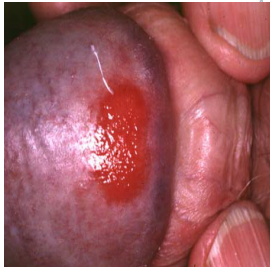

A moist, shiny, erythematous, well-demarcated plaque on the glans points to an older uncircumcised male is characteristic of Zoon's balanitis, also known as leukoerythroplakia. The condition is benign.



Pathogenesis: The pathogenesis of Zoon's balanitis is unclear. It is thought to be a form of leukoerythroplakia, which is a precancerous condition. The condition is characterized by a large, well-demarcated, erythematous plaque on the glans. The plaque is often associated with a moist, shiny appearance. The condition is benign and does not require treatment. However, if the plaque is large or symptomatic, it may be removed by circumcision or laser therapy.