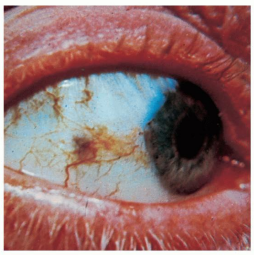

ALKAPTONURIA

(ochronosis).

Alkaptonuria , or homogentisic acid oxidase (HGO) deficiency, is a rare metabolic disorder. Excessive homogentisic acid (HGA) is excreted in the urine, which often turns dark, and HGA accumulates in connective tissues, including the dermis [49] (ochronosis).

Epidemiology

Alkaptonuria is inherited as an autosomal recessive trait. Pedigrees suggestive of a dominant mode of transmission contain a high degree of consanguinity and, when subjected to careful scrutiny, are actually found to show pseudodominance. In general populations, alkaptonuria is rare (1 in 250,000), but clusters of high incidence are found in certain groups with inbreeding (e.g., in Slovakia and Santo Domingo). Among Slovakian newborns the incidence is 1 in 19,000. Disease distribution is worldwide, and there is an approximately equal incidence in both sexes.

Etiology and Pathogenesis

The HGO gene maps to the q21-q23.60 region of chromosome 3. Multiple mutations have been found.[51-53] The mutations

change residues, which are conserved evolutionarily between Aspergillus HGO and human HGO, which suggests that they are fundamental to the activity of HGO. Both compound heterozygotes and homozygotes have been detected.

ALKAPTONURIA AT A GLANCE

- Autosomal recessive metabolic disease in which homogentisic acid, an intermediate product in the metabolism of phenylalanine and tyrosine, cannot be further metabolized (Online Mendelian Inheritance in Man #203500). The cause is a mutation in the homogentisate 1,2-dioxygenase acid oxidase gene on chromosome bands 3q21-q23.

- Clinical features are blue-black or gray discoloration of sclerae, face, pinnae, cartilage, and nails; dark sweat; arthritis; and homogentisic aciduria. Urine is dark after standing in alkaline pH.

- It is suggested that high tissue concentrations of ascorbic acid might delay and possibly reduce the degree of pathologic changes in the connective tissue.
- Differential diagnosis includes argyria, chrysiasis, and pigmentation after treatment with a miodarone and other medications.

- Prenatal diagnosis is possible through DNA analysis.

The biochemical pathway by which phenylalanine and tyrosine normally undergo oxidative degradation to acetoacetic acid is shown in Fig. 131-3. HGA (2,5-dihydroxyphenylacetic acid), the last molecule in the sequence to contain an intact aromatic ring, is cleaved to maleylacetoacetic acid (Fig. 131-5). The enzyme catalyzing ring cleavage, HGO, is normally present in the soluble fraction of liver and kidney cells. It is highly specific for HGA. HGO mRNA is found in liver, kidney, and prostate.
[54]

Atmospheric oxygen, ferrous ion, and

sulfhydryl
groups are required for enzymatic function. Quinones inhibit the enzyme. HGO activity is totally absent in both liver and kidney tissue from
alkaptonuric
subjects. In patients with
alkaptonuria
, HGA undergoes renal excretion or is transformed to
ochronotic
pigment within connective tissue. HGA may not be present in the first days of life due to the absence of enzymatic activity of other enzymes in the pathway of tyrosine catabolism.

The renal clearance of HGA is extremely high (up to 400 to 500 mL/minute) in both normal and alkaptonuric
subjects, which indicates active tubular secretion of HGA. This explains how with relatively low fasting plasma concentrations of HGA (in the range of 3 mg/
dL
) excretion may be up to 4 to 8 g/day in HGO deficiency. Compounds inhibiting this secretion may be an important factor in
ochronosis
. Once excreted, HGA (which is itself colorless in solution) gradually oxidizes to dark products. Oxidation occurs by degrees when the urine is exposed to air, but it can be hastened markedly by
alkalinization
. Urinary pH is the major variable causing the darkening of the urine, and some patients with acidic urine may never have spontaneously black urine. A diet high in protein or tyrosine increases the amount of HGA excreted in disease.

The precise manner by which HGA accumulation in tissues leads to ochronosis is only partially understood. A presumed HGA polymer has never been characterized.

Alkaptonuric mice (aku) do not have black urine or deposition of pigment, which is possibly related to the mouse's ability to synthesize ascorbic acid.

Experimental ochronosis induced by prolonged feeding of high-tyrosine diets

to rats may delineate the precise interaction between HGA and its products and connective tissue.[57] HGO also has been produced in experimental animals by L-phenylalanine feeding and diets deficient in sulfur amino acids or tryptophan and the iron chelator α,α′-dipyridyl.

HGA inhibits lysyl hydroxylase, an enzyme crucial for collagen cross-linking, in chick embryo ca lvaria
, which suggests that a reduction in the structural integrity of collagen consequent to deficient hydroxylysine
-derived cross-linkages may be responsible for cartilaginous degeneration in alkaptonuria.

Clinical Features

Dark urine is not always the initial manifestation of HGO deficiency. The urine is most apt to discolor rapidly when pH is above 7.0 and when reducing substances such as ascorbic acid, which normally protect HGA from oxidation, are not present in sufficient quantity. An early diagnosis of HGO deficiency is frequently made when (1) it is specifically sought because of family history, (2) discoloration of diapers occurs after cleansing in (alkaline) soap, (3) the urinary pH favors the oxidation of HGA, or (4) testing for urinary glucose with Benedict's solution yields an orange precipitate (which indicates a reducing substance) accompanied by a dark supernatant. A positive finding for Benedict's reaction and a negative result on glucose analysis with a glucose oxidase test reagent strongly suggest the diagnosis.

Although the diagnosis of alkaptonuria may be made during childhood, in rare cases the disorder is not detected until the individual develops pathologically significant changes in connective tissue in the third or fourth decade.[59] If coincidental renal disease prevents effective HGA excretion, the development of ochronosis
may be accelerated, and diffuse
hyperpigmentation
may result.

Dark brown or black cerumen may be present in the first decade, even in those younger than 5 years of age. Axillary skin pigmentation (greenish blue, blue, greenish yellow, or brown) in the pattern of glandular orifices may be present late in the first decade. This may be accompanied by staining of underwear (“sweat that stains”). A patient with pigmentary changes confined to sun-exposed areas has been described.[60]

A grayish blue tinge overlying ear cartilage is common in adulthood but is rarely seen before 20 years of age.[61] Ochronotic discoloration is rarely seen in childhood but is common in adulthood and can affect the sclera, cornea, conjunctiva, tarsus, and eyelid skin. Scleral involvement is noted in most patients[62,63] (Fig. 131-6). Scleral discoloration generally is restricted to that portion of the globe exposed by the palpebral fissure. The scleral pigmentation is usually triangular, with the base of the triangle facing the cornea. Tiny “oil droplets” of ochronotic pigment appear at the inner and outer poles of the corneas in advanced ochronosis. Later in the disease, structural changes result in loss of transillumination, stiffening, irregular contours, and eventually, in the third decade, calcification of the pinnae. The tympanic membrane may be blue. Tinnitus and variable degrees of deafness have been ascribed to ochronotic degeneration of the tympanic membrane and underlying ossicles. Laryngeal and tracheal cartilage becomes heavily pigmented but is asymptomatic.

The visible changes that occur with the passage of time are primarily due to the formation of oc hronotic

pigment granules in the dermis and sweat follicles and, most important, to the transmission of ochronotic
discoloration through thin areas of skin overlying pigmented cartilage and tendon. The latter pigmentation, which is fairly uniform in
ochronosis
, is most apparent at the nose tip, ear,
costochondral
junctions, and extensor tendons of the hands. Pigmented colloid
milium
on the dorsa of the hands have been reported.
[64]
Pigmentation of the skin is less prominent but may occur in a butterfly pattern on the nose and cheeks and even the palms as a presenting sign. Rarely, bluish gray fingernails and intensely dark nevi have been reported. Exogenous
ochronosis
and
striae
atrophicae
may follow the use of bleaching creams.

Insidious progression of ochronotic arthropathy, which generally begins in the third and fourth decades in men and approximately 10 years later in women, is the most disabling manifestation of alkaptonuria. [67] The disease is more severe in males. Bouts of acute inflammation may occur. Hip, knee, and shoulder limitation is an early sign. Lumbar pain, lordosi
s , kyph
osis ,
and sciatica are common. Radiographs show a characteristic appearance of early calcification of the
intervertebral
disk and later narrowing of the
intervertebral
spaces, with eventual disk collapse and progressive loss of height (Fig. 131-8). The hands and feet generally are spared.
Pseudogout
may coexist with
ochronosis
.

There is some suggestion of an increased incidence of cardiovascular disease in patients with o chronosis
, but accelerated arteriosclerosis has not been clearly documented. At postmortem examination,

pigmentation is commonly observed in the heart valves and annuli and in arteriosclerotic plaques.[68]

Prostatic symptoms in older men frequently are due to the formation of soft pigmented calculi in the alkaline secretions of the ducts and sinuses of that gland. Porous black renal stones containing calcium, phosphate, and oxalate also have been reported. The prostate has high levels of HGO mRNA, which may explain the black prostate calculi that are occasionally present in the disease.

Laboratory Findings

Aside from the excretion of HGA, alkaptonuric patients show no abnormalities on routine clinical laboratory tests. Normal individuals do not excrete HGA; therefore, darkening of the urine on the addition of sodium hydroxide is presumptive evidence of alkaptonuria.

Other tests based on the reducing properties of HGA include the black reaction after treatment with $FeCl_3$ and blackening of photographic emulsion paper on application of a drop of alkaptonuric urine followed by a drop of sodium hydroxide. Specific identification and quantification of urinary (as well as blood) HGA can be achieved by the use of a direct

spectrophotometric
method using HGO or with high-performance liquid chromatography or stable isotopes.

With the development of ochronotic arthropathy, radiographs of the spine show characteristic disk calcification, which occurs rarely in other forms of
spondylitis
.
Periostitis
, ligament calcification, and sacroiliac sclerosis are not features of
ochronotic
spondylitis

PATHOLOGY

Yellow to light-brown (ochre) pigment granules, which led to the original designation of ochronosis , are
present as free bodies and in dermal macrophages.
[69]

Irregular masses may be over 100 µm in diameter. The pigment, in contrast to melanin, is not bleached by 10 percent H_2O_2 after 72 hours.
[69]

Routine special stains for melanin react with the
ochronotic
pigment.

Electron microscopic studies show smaller-sized homogeneous bodies fusing to form larger

non-membrane-bound structures.[69] Although the original pigment is brown, Tyndall scattering of light makes involved skin appear blue.

The tendency of connective tissue, cartilage in particular, to darken gradually over the years constitutes the cardinal pathologic finding in alkaptonuria. Intervertebral disks are pigmented (jet black) and darken when examined.
Articular
cartilage, when heavily pigmented, displays the degenerative changes of fibrillation, fissuring, fragmentation, and erosion to bare bone.
Phagocytosis
of collagen fibrils is found in
synovial
macrophages.

Diagnosis and Differential Diagnosis

The diagnosis of alkaptonuria may be made on the basis of typical urinary discoloration or may await the onset of ochronosis in adulthood. Inasmuch as the disease behaves in a quite stereotypical manner with few confusing variants in its mode of presentation, it has been concluded that the diagnosis need only be thought of to be made.
Other causes of dark urine— melani
nuria , p
orphyria
,
myoglobinuria
,
bilirubinuria
, and
hematuria
—should not to be confused with
alkaptonuria
. An

ochronosis
-like pigmentation of skin and cartilage has been produced
iatrogenically
by
quinacrine
administration over a period of months and at the site of quinine injections.
[69]

Pigmentation due to
antimalarial
treatment is usually much more pronounced on mucosal surfaces and will fluoresce with a Wood's lamp. A slate gray to blue pigmentation in sun-exposed sites occurs after
amiodarone
treatment, and similar discoloration also involving the mucous membranes is seen in
argyria
and
chrysiasis
(Box 131-5).

Box 131-5 Differential Diagnosis of Alkaptonuria

Main Features

- Skin
- Black-gray skin on ear cartilage.

- Eyes
- Brown to black pigmentation of the sclera

- Rheumatologic features
- Skeletal pathologies, including spinal degeneration with kyphosis
- Ochronotic arthritis and arthropathy
- Thickened Achilles tendon

- Miscellaneous
- Urolithiasis
- Ochronotic prostate stones
- Aortic and mitral valve calcification

Consider

- Exogenous ochronosis
- Argyria
- Chrysiasis
- Treatment-induced pigmentation (amiodarone, quinacrine, quinine)

It is possible that the reversible ochronotic pigmentation caused by prolonged carbolic acid treatment is due to polymerization of the carbolic acid by HGA
polyphenol
oxidase
to an HGA polymer-like substance that differs from the polymer found in the genetic disease by the reversibility of the polymerization.

Exogenous ochronosis and pigmented colloid milia have been reported in a number of South Africans who used hydroquinone bleaching creams at strengths greater than 2 percent for a prolonged period.[66,71,72] Forty-two percent of women and 15 percent of men who used
hydroquinones
developed exogenous ochronosis.[72]
A similar condition has been seen in American blacks.

Treatment

The course of alkaptonuria is generally slow but irreversible. Treatment is primarily supportive, with close observation for the development of arthropathy, cardiac disease, and urinary tract disease (Box 131-6). Appropriate management includes genetic counseling, pain management with
nonsteroidal
anti-inflammatory agents, physical therapy to increase range of motion, and

regular follow-up visits.[20] Avoidance of high-protein, high-phenylalanine, and high-tyrosine diets has been reported to be important. A well-balanced normal diet seems the best approach during childhood. It has been postulated that large amounts of dietary vitamin C may be helpful, because vitamin C protects HGA against oxidation and thus may prevent the deposition of ochronotic
pigment; however, no long-term clinical studies have been undertaken to verify the effectiveness of this approach.

Box 131-6 Treatment of Alkaptonuria

- Avoidance of high-protein diet
- Avoidance of high-phenylalanine diet
- Avoidance of high-tyrosine diet
- Large amounts of dietary vitamin C
- 2(-2-nitro-4-trifluoromethylbenzoyl)-1,3-cyclohexanedione

It is disappointing that despite advances in our biochemical understanding of alkaptonuria and the disposition of accumulated HGA to form
ochronotic
pigment in connective tissue, this information has yet to be translated into a successful therapeutic program for managing the disease. Exogenous
cutaneous
ochronosis
induced by hydroquinone has been treated with the carbon dioxide laser.
[79]

Course and Prognosis

The ultimate course in adults with alkaptonuria is that of increasing pigmentation and skeletal incapacity. Little can be done to interrupt this progression; however, the disease is not incompatible with a normal life span, and the oldest patient on record lived to 99 years of age.

Exogenous Ochronosis.

Exogenous ochronosis results from the use of certain medications, which form an homogentistic acid polymer-like substance during their metabolism. It presents as an asymptomatic hyperpigmentation of the face, sides and back of the neck, back, and extensor sites of the extremities . Histopathologically, there is a collection of yellowish-brown (ochronotic) globules in the papillary dermis. There is no articular, renal, or cardiovascular involvement. It has been most frequently reported in association with hydroquinone (bleaching creams), usually in skin phototype VI patients, although it has been described in other skin types. Exogenous ochronosis has also been noticed after the use of antimalarials and products containing resorcinol, phenol, mercury, and picric acid. Treatment is rarely helpful, but the offending drug should be stopped to prevent progression. For POEMS syndrome and Cronkhite-Canada syndrome, see on-line version.